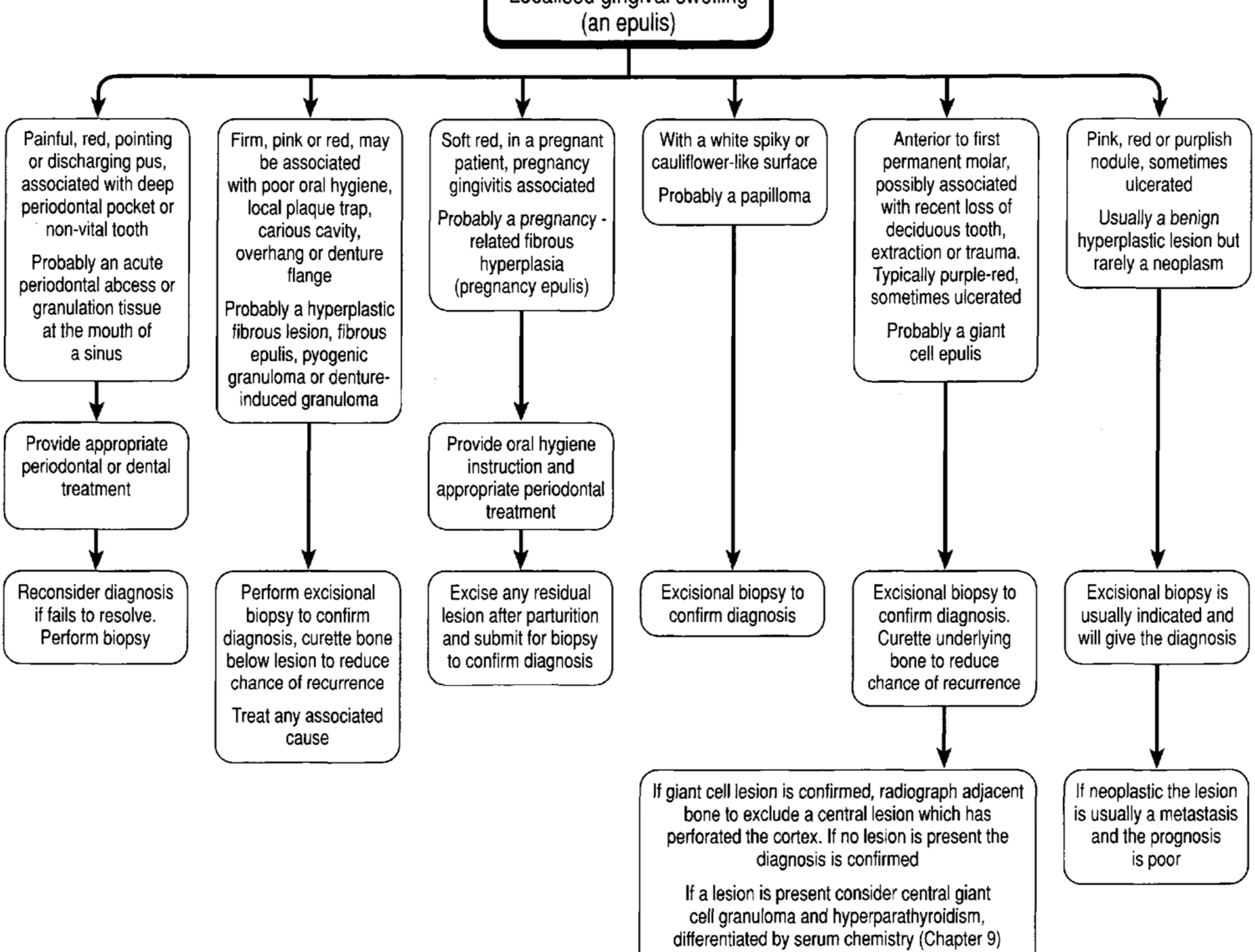
Localized gingival swelling (an epulis)
Painful, red, pointing or discharging pus, associated with deep periodontal pocket or non-vital tooth
Probably an acute periodontal abcess or granulation tissue at the mouth of a sinus
Provide appropriate periodontal or dental treatment
Reconsider diagnosis if fails to resolve. Perform biopsy
Firm, pink or red, may be associated with poor oral hygiene, local plaque trap, carious cavity, overhang or denture flange
Probably a hyperplastic fibrous lesion, fibrous epulis, pyogenic granuloma or denture-induced granuloma
Perform excisional biopsy to confirm diagnosis, curette bone below lesion to reduce chance of recurrence
Treat any associated cause
Soft red, in a pregnant patient, pregnancy gingivitis associated
Probably a pregnancy - related fibrous hyperplasia (pregnancy epulis)
Provide oral hygiene instruction and appropriate periodontal treatment
Excise any residual lesion after parturition and submit for biopsy to confirm diagnosis
With a white spiky or cauliflower-like surface
Probably a papilloma
Excisional biopsy to confirm diagnosis
Anterior to first permanent molar, possibly associated with recent loss of deciduous tooth, extraction or trauma. Typically purple-red, sometimes ulcerated
Probably a giant cell epulis
Excisional biopsy to confirm diagnosis. Curette underlying bone to reduce chance of recurrence
If giant cell lesion is confirmed, radiograph adjacent bone to exclude a central lesion which has perforated the cortex. If no lesion is present the diagnosis is confirmed
If a lesion is present consider central giant cell granuloma and hyperparathyroidism, differentiated by serum chemistry (Chapter 9)
Pink, red or purplish nodule, sometimes ulcerated
Usually a benign hyperplastic lesion but rarely a neoplasm
Excisional biopsy is usually indicated and will give the diagnosis
If neoplastic the lesion is usually a metastasis and the prognosis is poor